

VISUAL LUNG-SOUND CHARACTERIZATION BY TIME-EXPANDED WAVE-FORM ANALYSIS

RAYMOND L. H. MURPHY, JR., M.D., M.P.H., D.Sc., STEPHEN K. HOLFORD, S.M., AND WILLIAM C. KNOWLER, M.D., M.P.H.

Abstract To characterize lung sounds objectively, we examined, by means of time-amplitude plots, selected tape recordings of auscultatory phenomena considered by six observers to be typical of those in a standard classification. Normal lung sounds could not consistently be visually distinguished from adventitious sounds at conventional chart recorder speeds of 100mm per second or less, but the differentiation was easily achieved when the time scale of the plots was raised to 800 mm per second. When discontinuous

THE clinical usefulness of lung sounds has been limited by difficulties in verbal description: "It almost seems as if every physician has his own classification."¹ Visual displays by frequency spectral-analysis techniques and amplitude-versus-time plots²⁻¹¹ have not resulted in a clear, objective separation of these sounds. We observed that plotting sound amplitude versus time at scales above 400 mm per second showed details of the sound wave form obscured at the slower chart speeds in previous reports. Accordingly, we studied the reliability of this "time-expanded" method for characterization of chest sounds.

MATERIAL AND METHODS

Recording Technique

We recorded lung sounds by placing a Kent Cambridge Leatham-type stethoscope microphone on the chest at sites where examples of normal and abnormal sounds had been found, as previously described.^{12,13} The subjects were asked to breathe deeply through their mouths as in clinical practice. Sounds were preamplified and monitored during recording on a Tandberg Model 3000X tape recorder at tape speeds at or above 95.75 mm per second.

Selection of Typical Sounds

From a data base of over 1000 such recordings, examples of common auscultatory phenomena were selected by one of us (R.L.H.M.). Sounds considered to be typical examples of each of the categories in a standard classification¹ were reviewed by six observers. Including only those on which there was unanimous agreement in classification provided over 100 examples of discontinuous sounds, or rales, and 50 examples of continuous sounds, or rhonchi. For comparison, we examined several typical pleural friction rubs, normal tracheal and vesicular sounds, and some common artifactual sounds. We also analyzed commercial teaching tapes and tapes provided to us by other investigators.* When necessary, we used the standard scheme to reclassify the sounds.

Time-Base Expansion

We made time-expanded amplitude plots using a computer system by sampling the amplitude of the sound at regular intervals, storing the values in a memory and replaying the signal at a slower

rate. Adequate sampling rates and anti-aliasing and reconstruction filters were used to ensure the fidelity of the replayed wave forms. The sound reproduced by the computer could be plotted on a chart recorder sensitive to frequencies only up to 100 Hz with a paper speed of 25 mm per second. For example, sampling the amplitude of the chest sound 10,000 times per second and then replaying it at a rate of 156 samples per second was the equivalent of having plotted the original signal on a chart recorder with a much higher paper speed of 1600 mm per second and frequency sensitivity up to 4500Hz, the limit imposed by the aliasing filter. We then examined the time-expanded wave forms of these typical or classic sounds visually.

rate. Adequate sampling rates and anti-aliasing and reconstruction filters were used to ensure the fidelity of the replayed wave forms. The sound reproduced by the computer could be plotted on a chart recorder sensitive to frequencies only up to 100 Hz with a paper speed of 25 mm per second. For example, sampling the amplitude of the chest sound 10,000 times per second and then replaying it at a rate of 156 samples per second was the equivalent of having plotted the original signal on a chart recorder with a much higher paper speed of 1600 mm per second and frequency sensitivity up to 4500Hz, the limit imposed by the aliasing filter. We then examined the time-expanded wave forms of these typical or classic sounds visually.

RESULTS

The time-expanded wave forms of the typical sounds showed patterns that allowed the various categories of sound to be visually distinguished from one another. Such differentiation could not be reliably made from wave forms plotted at conventional chart recorder speeds (Fig. 1). In every case in which rales were heard clinically, the resulting wave forms showed intermittent "discontinuous" deflections usually less than 10 msec in duration. When rhonchi had been heard, the deflections were of much longer duration, usually more than 250 msec. Rales had waveforms appearing as more rapid or higher-frequency oscillations intermittently superimposed on the normal breath sound pattern. Rhonchi replaced this normal pattern, as shown in Figure 1. "Rale" and "rhonchi" patterns were distinct from those of the normal vesicular and tracheal sounds shown in parts (a) and (e) of Figure 1 as well as from those of artifacts (Fig. 2).

Our conclusions were confirmed on analysis of the tapes made by other workers. For example, plots of "crackles and wheezes" provided to us by Forgacs, who had advocated these names for adventitious lung

Druger G (The Chest: Its signs and sounds [book and tapes]. Humetrics Corp, 1973); Cugell D, Weiss F (Vol 12 of American College of Chest Physicians Audiographic Series); Forgacs P (personal communication of taped lung sounds); & Donnerberg R, et al (Physical findings of auscultation in normal chests and in bronchopulmonary diseases in adults [tape recording]. Dept of Medicine, Ohio State University).

A preliminary version of this paper entitled "Use and Limitations of Time-Expanded Waveforms in Differentiating Lung Sounds" was presented at the First International Conference on Lung Sounds, Boston, MA, October 14, 1976. From the Pulmonary services, Lemuel Shattuck and Faulkner hospitals, Boston, MA (address reprint requests to Dr. Murphy at the Pulmonary Service, Faulkner Hospital, 1153 Centre St., Jamaica Plain, MA 02130). Supported in part by a grant from the Institute of Occupational and Environmental Health, Montreal, PQ, Canada, and a Pulmonary SCOR grant (HL 15063).

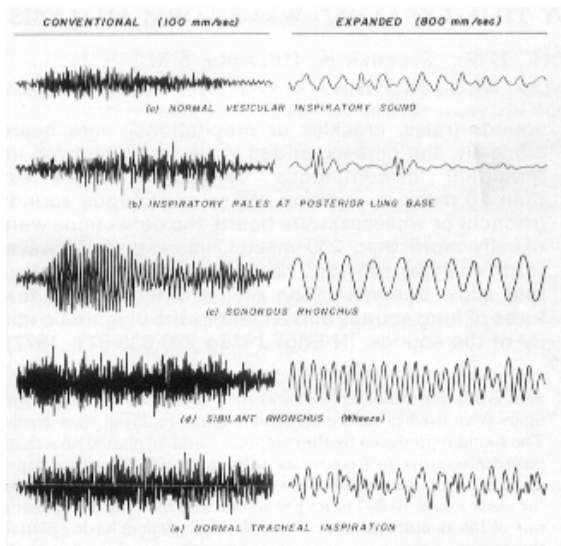


Figure 1. Amplitude-versus-Time Plots of Typical Lung Sounds, Showing that the Expanded Time Scales in the Right Column Reveal Visually Distinct Patterns Not Readily Seen in the Plots at Conventional Speeds on the Left.

Time is on the horizontal axis, and amplitude on the vertical axis. The plots on the right, reproduced here at a scale of 400mm per second, are 0.1 sec long and are sections from the 0.8-sec-long plots on the left shown here at 50 mm per second.

sounds, demonstrated that crackles were “discontinuous” and wheezes were “continuous” and that they had patterns identical in character to those of the rales and rhonchi in Figure 1.

Rhonchi

In tracings of both sonorous and sibilant rhonchi, the normal pattern is replaced by a more regular waveform whose duration of 250 msec or more is much longer than the “rale” pattern. As shown in Figure 1, the wave form of a sibilant rhonchus from an asthmatic patient had a greater number of deflections per unit time than the wave form of a sonorous rhonchus from a patient with bronchitis. Spectral analysis of these typical examples confirmed that the sibilant rhonchi had peaks of energy content at higher frequencies than the sonorous rhonchi. The lowest peaks observed in rhonchi classified by us as sibilant were in the range of 200 to 400 Hz as compared to 80 to 200Hz for sonorous rhonchi. The frequency content of rhonchi was seen to vary during the respiratory cycle as reported by Wooten and Waring.⁶

Rales

Most audible rales appear as unexpected deflections of 10 msec or less having an amplitude greater than that of the underlying wave form. Their duration ranges from about 1 to 10 msec. Rale patterns show a great diversity; the words fine, medium, and

coarse were inadequate to describe all the differences that we saw. Variations in the period of the deflections — that is, the length in time of the individual cycles — and in the total number of cycles seem to be the most noteworthy distinguishing features. The tracings of fine rales heard in patients with pulmonary fibrosis showed shorter periods and overall duration, and thus higher frequency content, than we saw in tracings of coarse rales from patients with pneumonia.

Occasionally, rales were so numerous that they be-came almost “continuous.” This phenomenon occurred in less than 5 per cent of our typical examples.

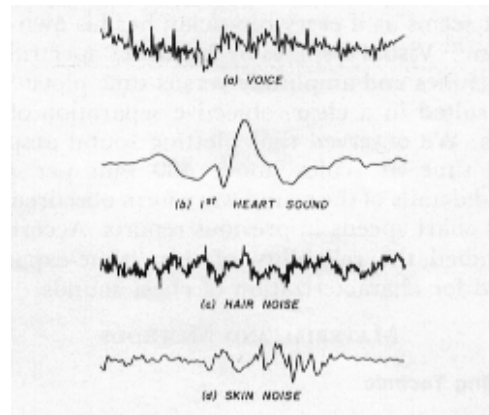


Figure 2. Artifactual Sounds.

When plotted at 400 mm per second, the wave forms of artifactual sounds are seen to have different patterns from the lung sounds in Figure 1. (a) shows voiced sounds recorded with the microphone on the subjects chest, (b) first heart sound recorded on the left anterior part of the chest in the mid-clavicular line at the fifth intercostal space, (C) vesicular sound with superimposed noise of the microphone moving over chest hair, and (d) plot of sound resulting from sliding the stethoscope across the skin.

In all these cases, characteristic intermittent rale patterns were observed in the same tracings. Even when confluent, the wave forms had the irregular rale pattern rather than the smooth, more uniform deflections of rhonchi. For our typical examples, then, the practical utility of categorizing sounds as “discontinuous” or “continuous” was demonstrated. It is not known whether this categorization would apply equally well if less than typical sounds had been selected.

DISCUSSION

Since Laennec’s invention of the stethoscope, many studies have attempted to analyze and visually display lung sounds. They have focused both on the amplitude of the sound over time, or temporal proper-

ties, and on analysis of the sound by component frequencies, or spectral properties.^{2-4,6-15} Cabot and Dodge were able to show, in 1925, that coarse and fine rales were associated with conspicuous low-frequency and high-frequency components respectively.¹⁰ Similarly, in 1955 McKusick et al. demonstrated that the spectrograms of "moist" and "dry crackling" rales were different, the dry rales containing more high frequencies.² Calibrated amplitude plots by Weiss and Carlson³ allowed visual perception of the overall amplitude of sounds, including pauses and duration differences as well as study of the relation of the amplitudes of inspiration and expiration. Adventitious sounds were not clearly distinguished by this method or by the integrating envelope detector de-scribed by Wooten and Waring.⁶

Forgacs, in 1967,¹⁶ pointed out that the study of crackling was difficult because the sounds follow one another so rapidly that neither the individual crackles nor the rhythmical pattern made by their sequence can be identified with the unaided ear. He observed that when these sounds were recorded on fast-moving magnetic tape and were played back slowly, the repetitive rhythm of a series of crackles could be seen in successive respiratory cycles. Two years later, he commented that the recording of wheezes in visual form had none of the advantages of phonocardiography because pen recordings are too slow to show the rapid oscillations of a wheeze clearly enough to distinguish them from the pattern of other lung sounds.¹⁷ He noted that the oscilloscope showed the regular wave forms of a wheeze but only at time-base speeds at which one saw such a small section of sound that it was very difficult to judge the timing of the wheezes in relation to the respiratory cycle.

Nath and Capel^{18,19} confirmed the repetitive nature of rales in some patients, but their published tracings, as well as those of Forgacs, had time scales below 100 mm per second and did not clearly reveal the wave form characteristics of the adventitious sounds. The amplitude deflections produced by rales, for example, are similar to deflections found in tracings in which no rales are described since the specific waveforms of the rales are obscured at this speed. In our experience, the time base of the amplitude-versus-time plot must be approximately 400 mm per second or more to allow visual separation of lung sounds. Measurements on the tracings are more easily made when the time base is above 1500 mm per second. For example, individual rales are most conveniently examined on plots with time scales of about 6000 mm per second. Although we have used a computer to produce the plots presented in this report, simpler techniques could be used, such as direct plotting on fast chart recorders or time-base expansion by frequency-modulation tape recorders, but they lack the flexibility of the computer method.

Rales are sensitive to microphone characteristics,

and the shapes of the rale complexes in tracings maybe affected by the type of microphone used. Standardization of chest-microphone characteristics and development of clinically practical techniques for attachment to the chest wall are needed.

We have observed that as flow at the mouth varies, the appearance of rales on the time-expanded plots remains that of a short, transient oscillation. Others have shown that the time of occurrence of inspiratory rates is not closely related to flow at the mouth.¹⁸ Sibilant rhonchi (wheezes) change in character with flow,¹⁶ but both sibilant and sonorous rhonchi appear as continuous oscillations on the time-expanded plots despite such alterations in flow.

The generality of our results may be limited by our selection of classic or typical sounds rather than all sounds from a known disease or from a random sample of a general population, with the consequent systematic exclusion of sounds not easily classified. This procedure facilitated testing the question of most concern to us — namely, whether the time expansion could separate sounds readily recognized by ear. Although we conclude that it can, we recognize the need for more comprehensive investigations of specific diseases as well as population-based studies so that all types of lung sounds will be included. We are confident, however, that we have studied the common phenomena likely to be encountered in routine practice.

Although we have not explored the clinical utility in depth, we have been able to document rales objectively in patients with congestive heart failure in the intensive-care setting, as well as the disappearance of the characteristic wave-form complexes after diuretic therapy. This factor could potentially facilitate such observations by paramedical personnel. We have also been using the technique in industrial surveys of asbestos workers to document the characteristic rales and to count them. We are encouraged in this regard because our method avoids the problems of intra-observer variability inherent in chest auscultation, as we have discussed in detail previously.^{12,13} It is likely that time expansion could aid in observer-variability studies as well as in more accurate characterization of sound transmission and generation, but this possibility also awaits future study. In any case, we believe that time-expanded wave-form analysis provides a scientific method for differentiating the various lung sounds that will facilitate further objective investigation of their diagnostic utility.

We are indebted to Drs. Paul Forgacs, Earle Weiss, David Cugell and Roy Donnerberg for providing lung-sound tapes, to Drs. Kenneth Stevens and William Henke, of the M.I.T. Research Laboratory of Electronics, for use of the MITSYN computer sound-processing system which is partially supported by a grant (NS 04332-11) from the National Institutes of Health, to Drs. Edward A. Gaensler and Robert Loudon for advice and to Elizabeth Del Bono and Lee Starr for technical assistance.

REFERENCES

1. Fraser RG, Pare JAP: Diagnosis of Diseases of the Chest. Philadelphia, WB Saunders. 1970.
 2. McKusick VA, Jenkins JT, Webb GN: The acoustic basis of the chest examination: studies by means of sound spectrography. Am Rev Tuberc 72:12-34, 1955
 3. Weiss FR, Carison CJ: Recording of breath sounds. Am Rev Respir Dis 105:835-839, 1972
 4. Grassi C, Marinone G, Puglisi M, et al: Normal and pathological respiratory sounds analyzed by means of a new phonopneumographic apparatus. Respiration 33:315-324, 1976.
 5. Cugell DW: Use of tape recordings of respiratory sound and breathing pattern for instruction in pulmonary auscultation. Am Rev Respir Dis 104:948-950. 1971.
 6. Wooten FT, Waring WW: Spectral and intensity analysis of respiratory sounds. Proceedings of the 25th annual Conference on Engineering in Medicine and Biology. Arlington, Virginia, Alliance for Engineering in Medicine and Biology. 1972.
 7. Ebina T, Toshima M, Fukushi K, et al: Klinische Anwendung elektrisch registrierter Atemgeräusche. Beitr Klin Tub 115:276-281. 1956.
 8. Klebanov MA: Fonorespirografia i perspektivy ee ispol'zovaniia. Ter Arkh 41:57-63, 1969.
 9. Zislin DM, Rozenhiat VV, Likhacheva EI: Ob'ektivnoe issledovanie dykhatel'nykh shumov s pomoshch'iu chastotnogo analiza. Ter Arkh41:108-113, 1969
 10. Cabot RC, Dodge HF: Frequency characteristics of heart and lung sounds. JA MA 84:1793-1795. 1925.
 11. McKusick VA: Cardiovascular Sound in Health and Disease. Baltimore, Williams and Wilkins, 1958.
 12. Murphy RLH Jr, Sorensen K: Chest auscultation in the diagnosis of pulmonary asbestosis. J Occup Med 15:272-276, 1973.
 13. Murphy RLI-I: Human factors in chest auscultation, Human Factors in Health Care. Edited by RM Pickett. TJ Triggs. Lexington, Massachusetts. DC Heath, 1975.
 14. Jalil A, Aronovitch M: Recording and analysis of breath sounds in patients of chest disease. Indian J Chest Dis 8:158-194.1966.
 15. Banaszak EF, Kory RC, Snider GI: Phonopneumography. Am Rev Respir Dis 107:449-455, 1973.
 16. Forgacs P: Crackles and wheezes. Lancet 2:203-205, 1967.
 17. *Idem*: Lung sounds. Br J Dis Chest 63:1-12, 1969.
 18. Nath AR, Capel LH: Inspiratory crackles and mechanical events of breathing. Thorax 29:695-698, 1974.
 19. *Idem*: Inspiratory crackles — early and late. Thorax 29:223-227, 1974
-